



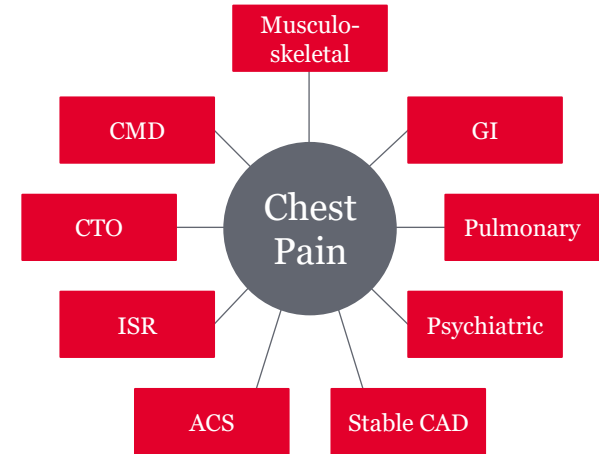
CMD PATIENT CASES

Managing INOCA Patients

CMD: Coronary Microvascular Dysfunction;
INOCA: Ischemia and No Obstructive Coronary Artery Disease
Information contained herein for DISTRIBUTION in Australia and New Zealand ONLY.
©2022 Abbott. All rights reserved. MAT-2415007 V1.0

Angiography Doesn't Tell the Whole Story

- **40-60%** of Chronic Coronary Syndrome (CCS) patients undergoing angiography have Ischemia and No Obstructive Coronary Artery Disease (INOCA)¹⁻³
- **Half of this patient population** may have angina due to Coronary Microvascular Dysfunction (CMD)³
- ESC guidelines⁴, EAPCI consensus document⁵ and AHA/ACC⁶ guidelines on Chest Pain recommend (Class IIA) wire-based measurement of IMR and CFR
- IMR/CFR assessment can help to objectively diagnose CMD^{3,5}
- A CMD diagnosis can tailor patient treatments towards improved angina score and quality of life⁷



CFR: coronary flow reserve; IMR: index of microcirculatory resistance

1. Patel MR, et al. *NEJM*. 2010; 362:886-895. DOI:10.1056/NEJMoao907272. 2. Maas A, et al. *EMJ Int Cardiol*. 2019; 7[Suppl 1] 2-17. 3. Marinescu MA, et al. *JACC Cardiovasc Imaging*. 2015;8:210-220. DOI:10.1016/j.jcmg.2014.12.008. 4. Knuuti et al. *EHJ* 2020; 41:407-477. DOI:10.1093/eurheartj/ehz425. 5. Kunadian V, et al. *EHJ & Eurointervention* 2020; ehaa503. DOI:10.1093/eurheartj/ehaa503. 6. Gulati M. et al. 2021 AHA/ACC/ASE/CHEST/SAEM/SCCT/SSCMR Guideline for the Evaluation and Diagnosis of Chest Pain: A report of the American College of Cardiology/American Heart Association Joint Committee on Clinical Practice Guidelines. 7. Ford TJ, et al. *JACC Intv*. 2020; 13:33-45. DOI:10.1016/j.jcin.2019.11.001.

Information contained herein for DISTRIBUTION in Australia and New Zealand ONLY.

©2022 Abbott. All rights reserved. MAT-2415007 V1.0

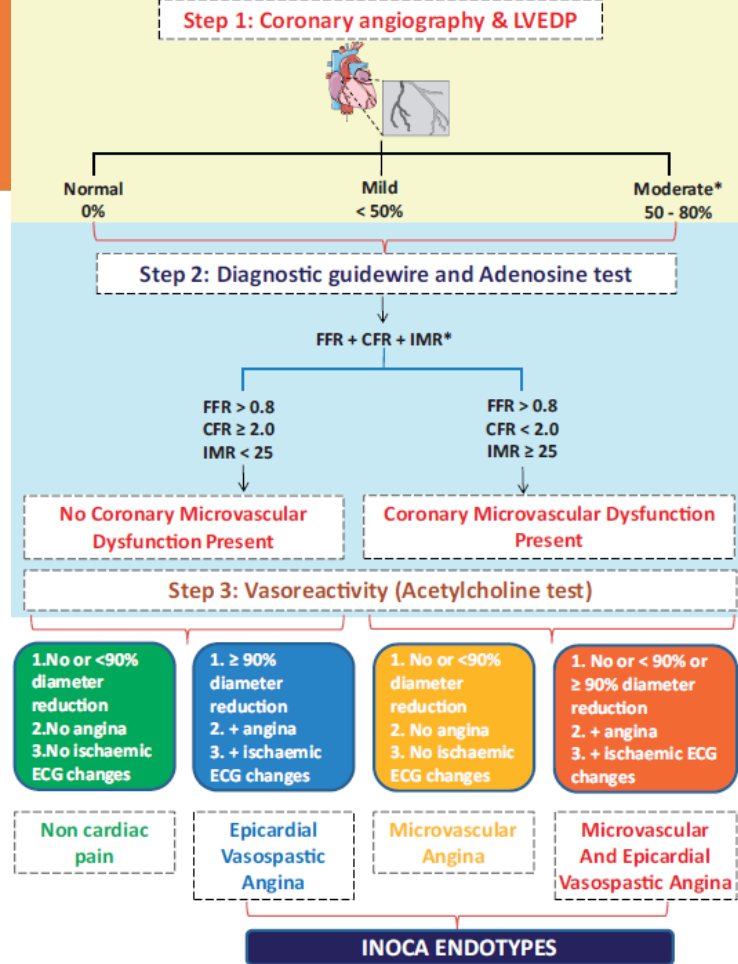
How to Evaluate INOCA

Guidelines by the EAPCI consensus document¹

CFR: coronary flow reserve; FCA: functional coronary angiography; FFR: fractional flow reserve; IMR: index of microcirculatory resistance; LVEDP: left ventricular end-diastolic pressure

1. Kunadian V, et al. *EHJ & Eurointervention* 2020: ehaa503.
DOI:10.1093/eurheartj/ehaa503.

Information contained herein for DISTRIBUTION in Australia and New Zealand ONLY.
©2022 Abbott. All rights reserved. MAT-2415007 V1.0



How Does Physiology Guide Treatment in These INOCA Patients?

- These patient cases have non-significant lesions (FFR > 0.80)¹
- However, they experience persistent angina
- A **comprehensive physiology** assessment can be used to diagnose both epicardial disease and coronary microvascular dysfunction towards **guiding patient treatment**¹

Patient	Angiography Results	Duration of Symptoms	FFR
1	INOCA	2 years	0.87
2	INOCA	7 years	0.92
3	Normal coronary arteries	2 years	0.91
4	Normal coronary arteries	6 years	0.91
5 (Post-PCI)	No relevant stenosis	1 year	0.91

1. Kunadian V, et al. *EHJ & Eurointervention* 2020: ehaa503. DOI:10.1093/eurheartj/ehaa503.



PATIENT 1

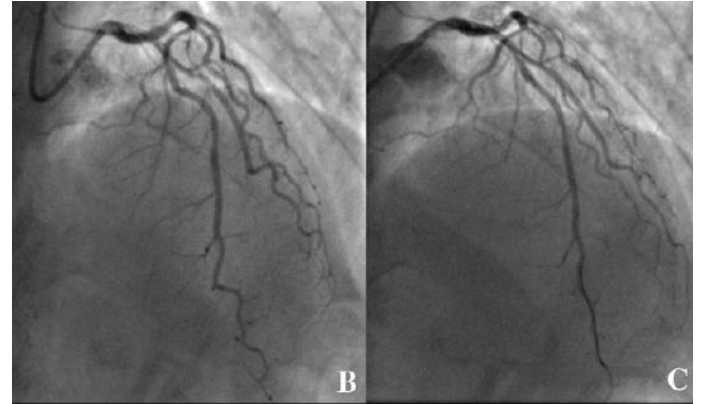
INOCA

Patient 1 Case: INOCA

Female, 59 years old

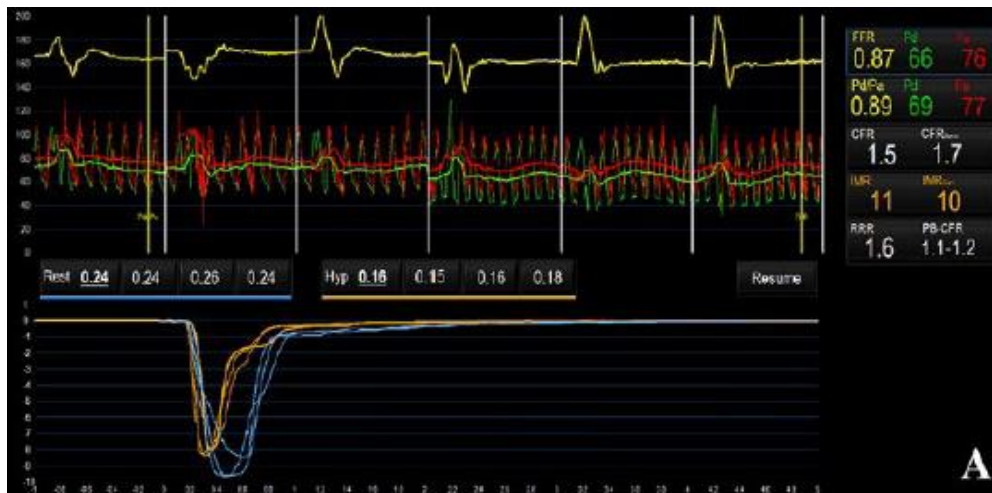
2 years history of predominantly exertional chest tightness radiating down left arm

- Past Medical History
 - Hyperlipidaemia
 - Previous hysterectomy
 - Fibromyalgia
 - Sciatica
- Invasive coronary angiography: calcified, **non-obstructive** (<50%) stenosis in proximal LAD



Sidik NP, et al. *European Heart Journal – Case Reports*; doi:10.1093/ehjcr/ytaa060

Patient 1 Case: INOCA



FFR=0.87

IMR= 11 (normal)

CFR= 1.5 (low)

Diagnosis: Possible CMD

Treatment:

Amlodipine and Bisoprolol switched to Verapamil (CCB)

Ramipril (ACE inhibitor)

Follow-up: Improvement of SAQ-PL from 44 to 47 at 4 months

- SAQ-PL is a patient's self-evaluation – the higher the score represents better (less severe)

ACE: angiotensin-converting enzyme; CCB: calcium channel blocker; SAQ-PL: Seattle Angina Questionnaire – Physical Limitation

Sidik NP, et al. *European Heart Journal* – Case Reports; doi:10.1093/ehjcr/ytaa060

Information contained herein for DISTRIBUTION in Australia and New Zealand ONLY.

©2022 Abbott. All rights reserved. MAT-2415007 V1.0



PATIENT 2

INOCA

Patient 2 Case: INOCA

Male, 52 years old

Patient presents with exertional chest pain, radiating to left arm

- Past Medical History
 - Type 2 DM
 - Hypertension
 - Dyslipidaemia
 - Family history of premature CAD
 - Obesity
 - TIA
- Myocardial perfusion scan: inducible ischemia
- Invasive coronary angiography: anomalous CX, **no obstruction**
- CTCA showing mild plaque disease only

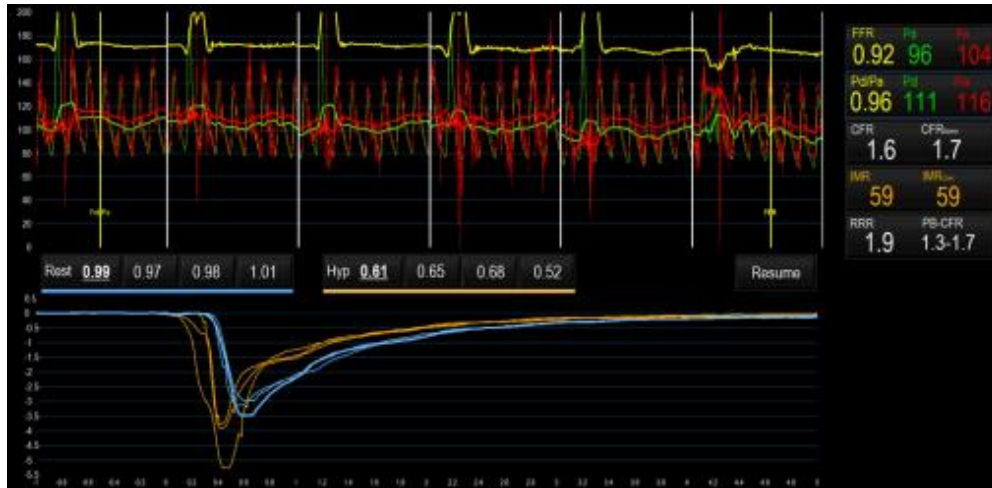


Maas A, et al. *EMJ Int Cardiol.* 2019;7[Suppl 1]2-17

Patient 2 Case: INOCA

Presenting again after 7 years of chronic angina with radiation to left arm, symptoms worsening since 1 year

- Anti-anginal therapy stopped



FFR=0.92
IMR= 59 (abnormal)
CFR= 1.6 (abnormal)

Diagnosis: CMD

Treatment:
Verapamil (CCB)

Maas A, et al. *EMJ Int Cardiol.* 2019;7[Suppl 1]2-17



PATIENT 3

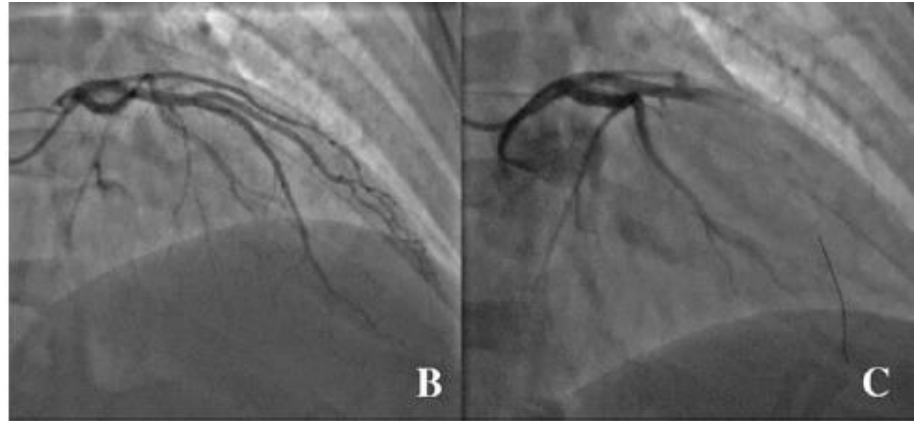
Normal Coronary Arteries

Patient 3 Case: Normal Coronary Arteries

Female, 42 years old

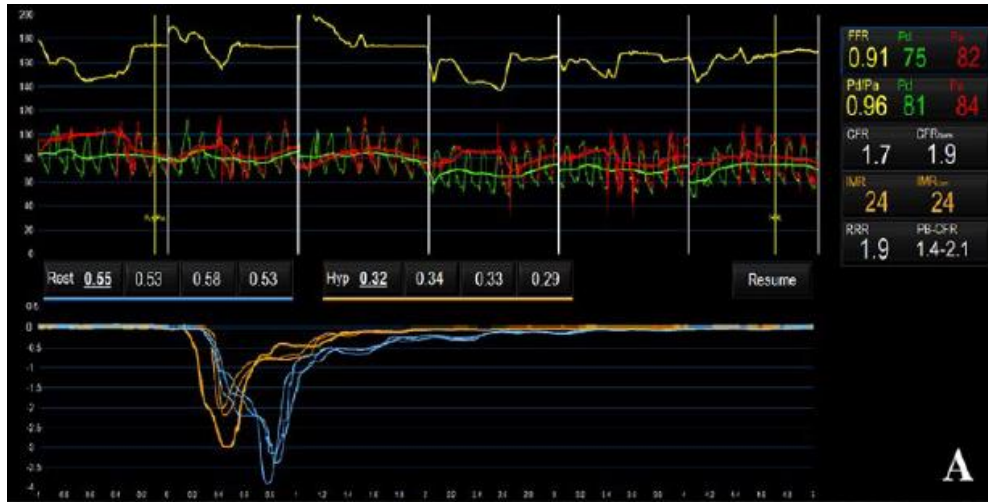2 years history of typical angina –
CCS class II

- Past Medical History
 - Anxiety and depression (on propranolol)
 - Ex-smoker
 - Obesity
 - Migraine
- Invasive coronary angiography:
normal coronary arteries



Sidik NP, et al. *European Heart Journal* – Case Reports; doi:10.1093/ehjcr/ytaa060

Patient 3 Case: Normal Coronary Arteries



FFR=0.91
IMR= 24 (borderline)
CFR= 1.7 (low)
Diagnosis: CMD
Treatment:
Verapamil (CCB)
Statin

Follow-up: Improvement of SAQ-PL from 55 to 72 at 4 months

- SAQ-PL is a patient's self-evaluation – the higher the score represents better (less severe)

Sidik NP, et al. *European Heart Journal – Case Reports*; doi:10.1093/ehjcr/ytaa060



PATIENT 4

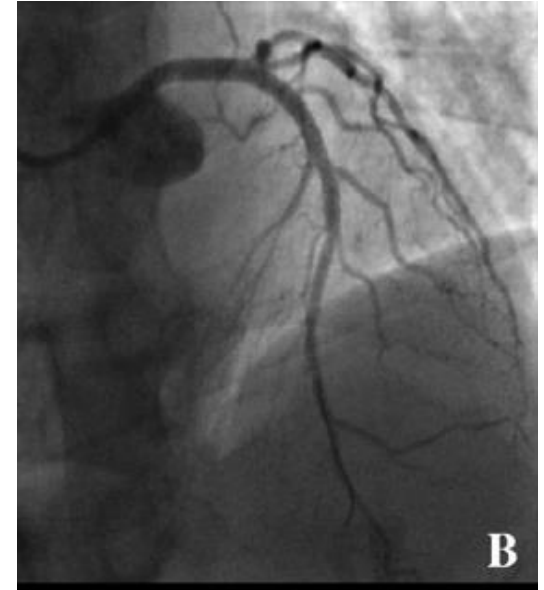
Normal Coronary Arteries (CMD-negative)

Patient 4 Case: Normal Coronary Arteries

Female, 46 years old

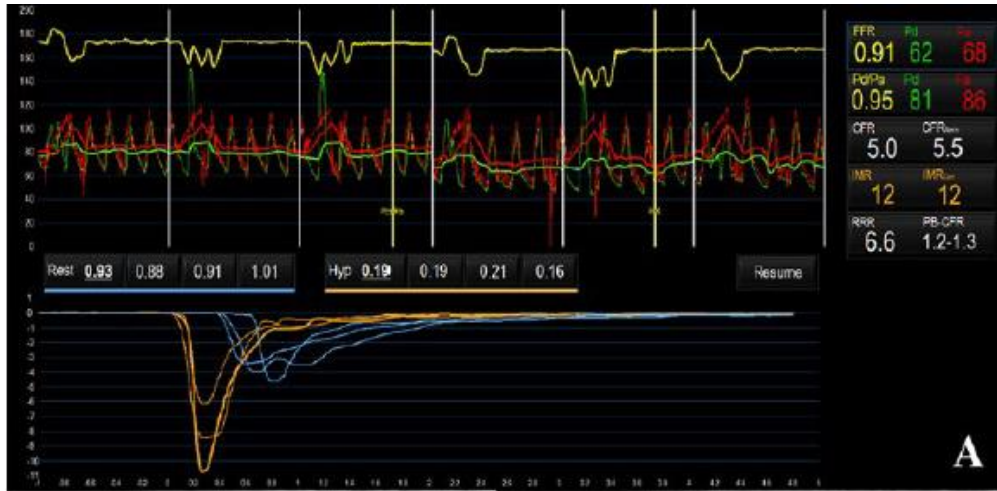6 years history of predominantly exertional chest tightness radiating to left shoulder

- Past Medical History
 - Emphysema
 - Depression
 - Osteoarthritis
 - IBS (normal gastroscopy and sigmoidoscopy)
 - Previous cholecystectomy
- Invasive coronary angiography:
normal coronary arteries



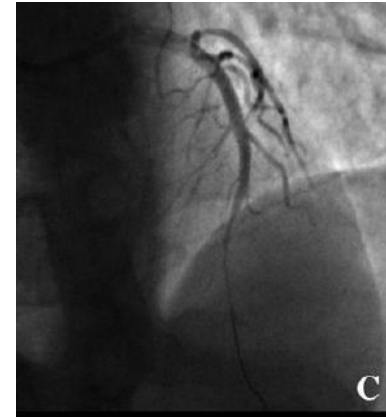
Sidik NP, et al. *European Heart Journal – Case Reports*; doi:10.1093/ehjcr/ytaa060

Patient 4 Case: Normal Coronary Arteries



FFR=0.91
IMR= 12 (normal)
CFR= 5.0 (normal)

Sidik NP, et al. *European Heart Journal – Case Reports*; doi:10.1093/ehjcr/ytaa060



On acetylcholine provocation testing, there was epicardial vasospasm from the mid to distal segment.

Diagnosis: Vasospastic angina

Treatment: Tildiem (CCB)



PATIENT 5

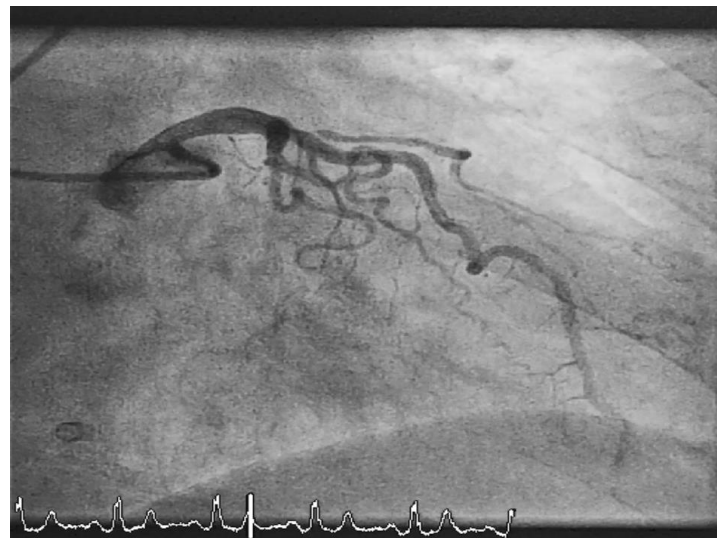Post-PCI INOCA

Patient 5 Case: Post-PCI INOCA

Female, 81 years old

3-vessel CAD

Hospitalization Date	Results
05.07.2018	Stent of the RCA (2 DES)
24.10.2018	Stent of RIVP (1 DES) and distal LAD (1 DES)
27.11.2018	No relevant stenosis, ostial stenosis of the LCX (small vessel)
09.2019	Angina CCS IV (cries in front of physician as she is desperate)



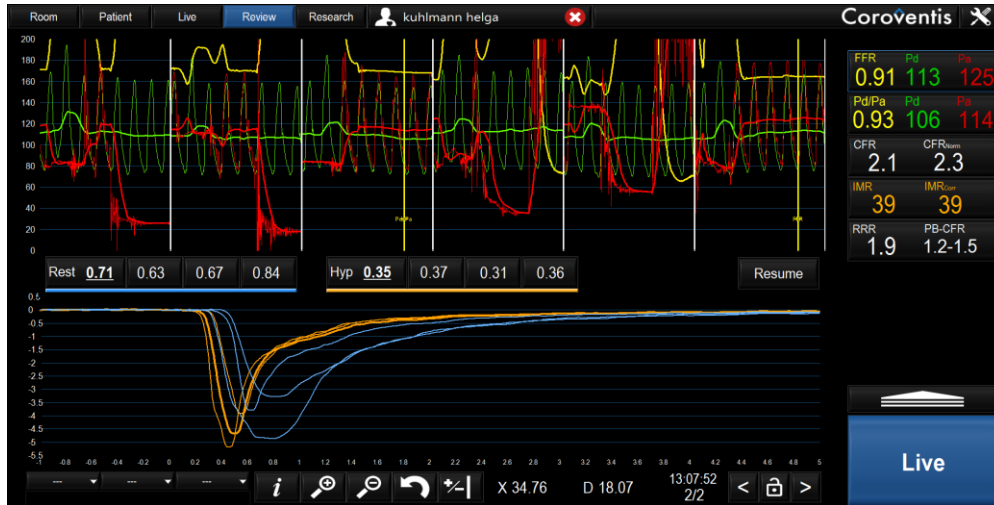
Case courtesy of Professor Tomasso Gori MD, PhD; Mainz, Germany

Data on file at Abbott

Information contained herein for DISTRIBUTION in Australia and New Zealand ONLY.

©2022 Abbott. All rights reserved. MAT-2415007 V1.0

Patient 5 Case: Post-PCI INOCA



FFR=0.91

IMR= 39 (abnormal)

CFR= 2.1 (borderline)

Diagnosis: CMD

Treatment:

Cocktail of medication including
Statin, Ranolazine, Beta Blocker, ACE,
CCB, Antidepressant

Follow-up: Improvement in angina at 6 months follow-up - CCS I

Case courtesy of Professor Tomasso Gori MD, PhD; Mainz, Germany

Data on file at Abbott

Information contained herein for DISTRIBUTION in Australia and New Zealand ONLY.

©2022 Abbott. All rights reserved. MAT-2415007 V1.0



Summary of Patient Cases and Treatment

Comprehensive Physiology Assessment Guides

Patient Treatment

Patient	Angiography Results	Duration of Symptoms	FFR	IMR/CFR	Diagnosis	Treatment
1	INOCA	2 years	0.87	11 / 1.5	Possible CMD	<ul style="list-style-type: none"> Verapamil (CCB) Ramipril (ACE inhibitor)
2	INOCA	7 years	0.92	59 / 1.6	CMD	<ul style="list-style-type: none"> Verapamil (CCB)
3	Normal coronary arteries	2 years	0.91	24 / 1.7	CMD	<ul style="list-style-type: none"> Verapamil (CCB) Statin therapy
4	Normal coronary arteries	6 years	0.91	12 / 5.0	Vasospastic angina	<ul style="list-style-type: none"> Tildiem (CCB)
5 (Post-PCI)	No relevant stenosis	1 year	0.91	39 / 2.1	CMD	<ul style="list-style-type: none"> Cocktail of medication including Statin, Ranolazine, beta blocker, ACE inhibitor, CCB, antidepressant


ACE: angiotensin-converting enzyme; CCB: calcium channel blocker

Summary

- INOCA is **not benign** and a large proportion of patients are believed to have Coronary Microvascular Dysfunction (CMD)¹
- CMD has varying clinical presentations, but can be objectively **diagnosed using IMR and CFR**^{1,2}
- New **EAPCI consensus**¹ guides the evaluation of INOCA for a CMD diagnosis
- A CMD diagnosis can be used to optimize individualized medical therapy to **improve angina and quality of life**^{1,3}
- PressureWire™ X Guidewire and CoroFlow‡ Cardiovascular System are the **only*** commercially available device that can assess for both epicardial disease and CMD in the cath lab^{3,4}

* With IMR, CFR, RFR and FFR

1. Kunadian V, et al. *EHJ & Eurointervention* 2020; ehaa503. DOI:10.1093/eurheartj/ehaa503. 2. Sidik NP, et al. *European Heart Journal – Case Reports* 2020. DOI:10.1093/ehjcr/ytaa060. 3. Ford TJ, et al. *JACC Intv.* 2020; 13:33-45. DOI:10.1016/j.jcin.2019.11.001. 4. PressureWire™ X Guidewire Instructions for Use (IFU). Refer to IFU for additional information. CoroFlow‡ Cardiovascular System IFU. Refer to IFU for additional information.



CAUTION: This product is intended for use by or under the direction of a physician. Prior to use, reference the Instructions for Use, inside the product carton (when available) or at *vascular.eifu.abbott* or at *medical.abbott/manuals* for more detailed information on Indications, Contraindications, Warnings, Precautions and Adverse Events. This material is intended for use with healthcare professionals only.

Information contained herein for DISTRIBUTION in Australia and New Zealand ONLY.

Illustrations are artist's representations only and should not be considered as engineering drawings or photographs. Photos on file at Abbott.

Abbott Vascular Division of Abbott Medical Australia Pty Ltd: 299 Lane Cove Road, Macquarie Park NSW 2113. Phone: 1800 550 939.

Abbott Vascular Division of Abbott Medical New Zealand Limited: Grd Flr, Bldg D, 4 Pacific Rise, Mount Wellington Auckland 1060. Phone: 0800 827 285

™ Indicates a trademark of the Abbott Group of Companies.

* Indicates a third-party trademark, which is property of its respective owner.



Abbott